



THE COLLEGE OF
OPTOMETRISTS

Stage Two

Overarching case scenario 15

AGE AND GENDER Female Aged 71 years

ETHNIC BACKGROUND Caucasian

OCCUPATION AND HOBBIES Retired cook: driver: Hobbies: reading, crosswords, jigsaws, swimming

PRESENTING SYMPTOMS AND HISTORY Routine 2-yearly recheck. Has noticed that floaters seem to have got worse over the past couple of days, usually has lots of small dots, but now has a large squiggle in vision along with lots more small dots. Unsure which eye. Perhaps the odd flash seen when looking to the side in the dark. Seen at hospital 5 years ago for a similar thing, told all ok and had no treatment. Dazzled by bright sunlight outdoors. Has given up driving at night and only drives familiar roads.

Mother had cataract.

GENERAL HEALTH AND MEDICATION Has medication to control high cholesterol and blood pressure level (for past 10 years)

PRESENT Rx, CENTRATION AND ACUITIES CR39 Single vision distance and near spectacles 2 years old. Can manage to read without Rx.

RE: -2.50/-1.00 x 60 6/9 Near Add +2.50 N8

LE: -3.00/-0.25 x 120 6/9 Near Add +2.50 N8

monoc ocs R 32 L 33

PD/NCD 65 (R32/L33) / 61 at 40cm

VISION RE: 3/60 LE: 2/60

PINHOLE VISION RE: 6/18 LE: 6/12

REFRACTION

RE: -3.00/-1.00 x 60 Near Add +3.00 N8

LE: -3.50/-0.50 x 120 Near Add +3.00 N8

VA Distance RE: 6/7.5 LE: 6/7.5 Binoc 6/6 just

ACCOMMODATION None

BINOCULAR STATUS

Distance cover test with Rx 4prism exophoria, good recovery

Near cover test with Rx 6prism exophoria, good recovery

MOTILITY full, no diplopia

PUPIL REACTIONS direct, consensual and near reflexes present, no RAPD

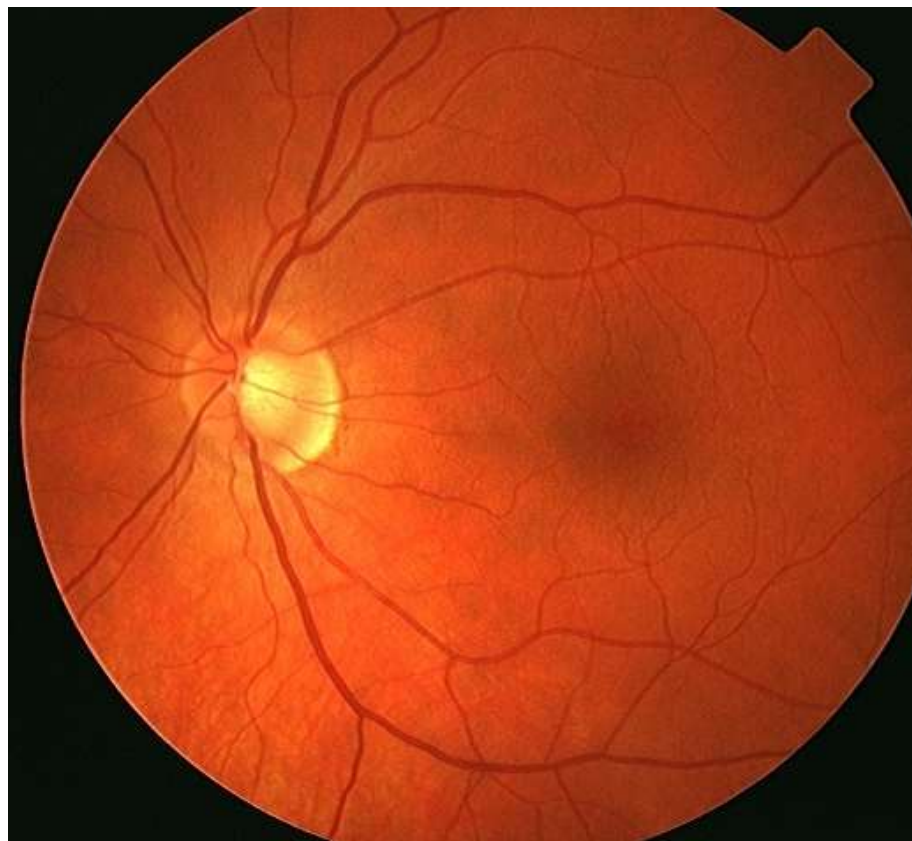
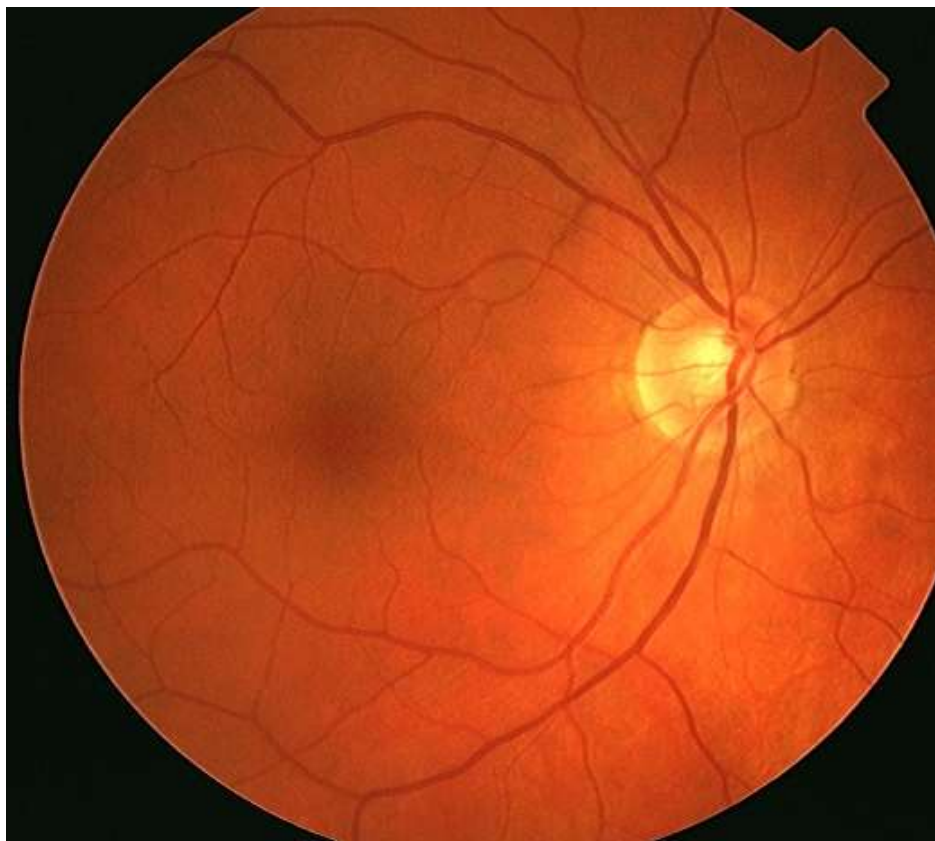
FUNDUS EXAMINATION see attached, lots of small brown looking floaters visible in RE. Also Weiss ring in LE

FIELDS see attached:

IOP RE: 11mmHg LE: 10mmHg AO NCT 10.30am

EXTERNAL EYE EXAMINATION all healthy

Fundus Image



Field RE & LE

